

Ultrasound Guided Erector Spinae Plane Block; an Alternative to Epidural Analgesia for Pain Management After Thoracotomy

Ultrason Eşliğinde Uygulanan Erektör Spina Plan Bloğu; Torakotomi Sonrası Ağrı Yönetiminde Epidural Analjeziye Bir Alternatif mi?

● Fatih Şimşek¹, ● Ufuk Turan², ● Hasan Kamburoğlu³, ● Hakan Işık⁴, ● Ömür İlban⁵,
● Gökhan Özkan¹, ● Serkan Şenkal¹

¹University of Health Sciences Türkiye, Gülhane Training and Research Hospital, Clinic of Anesthesiology and Reanimation, Ankara, Türkiye

²Bor State Hospital, Clinic of Anesthesiology and Reanimation, Niğde, Türkiye

³Acıbadem Ataşehir Hospital, Clinic of Anesthesiology and Reanimation, İstanbul, Türkiye

⁴University of Health Sciences Türkiye, Gülhane Training and Research Hospital, Clinic of Thoracic Surgery, Ankara, Türkiye

⁵Konya Numune Hospital, Clinic of Anesthesiology and Intensive Care, Konya, Türkiye

ABSTRACT

Background: Severe postoperative pain may occur following thoracotomy. The sources of this pain often include multiple muscle incisions, chest drains and possible rib injury. The management of this pain is extremely important for rehabilitation in the postoperative period. Thoracic epidural analgesia (TEA) represents the “gold standard” of pain control. However, this approach has serious problems such as hypotension, urinary retention, and hematoma. The erector spinae plane block (ESPB) is a novel regional analgesia technique and it is a simple, safe and effective method that can be applied as an alternative. The aim of this study was to assess the analgesic effectiveness of the ESPB and TEA techniques after thoracotomy.

Materials and Methods: This retrospective, single-center study conducted between October 2018 and September 2020. We evaluated 83 patients who received ESPB, TEA and conventional (non-regional) technique. Demographic data, operation type and duration, postoperative visual analog scale (VAS) scores, opioid consumption were obtained from anesthesia and clinical patient follow-up forms.

Results: The study included 83 patients who underwent thoracotomy and were divided into three groups as group ESPB (28), group TEA (33) and group control (22) who did not apply any regional analgesia method. The VAS scores at the 8th, 24th and 48th hours postoperatively, were found to be significantly lower in the ESPB and TEA groups compared to the control group ($p<0.05$). ESPB and TEA groups had similar levels of VAS scores and opioid consumption ($p>0.05$). Opioid consumptions of ESPB and TEA groups was significantly lower than that in the control group ($p<0.05$).

Conclusion: ESPB, which provides a similar level of analgesia with TEA in the management of postoperative analgesia in thoracotomy, can be considered a good alternative regional analgesia technique especially in patients with additional comorbidities such as obesity and spinal deformity.

Keywords: Thoracic surgery, postoperative pain management, regional analgesia, epidural analgesia, erector spinae plane block, opioid consumption

ÖZ

Amaç: Torakotomi sonrası şiddetli postoperatif ağrı meydana gelmektedir. Bu ağrının nedeni genellikle birden fazla kas kesiği, göğüs drenleri ve olası kaburga yaralanmalarını içerir. Ağrının yönetimi postoperatif dönemde rehabilitasyon için son derece önemlidir. Torasik epidural analjezi (TEA), ağrı kontrolünün “altın standardını” temsil eder. Ancak bu yaklaşımın hipotansiyon, idrar retansiyonu ve hematoma gibi ciddi komplikasyonları bulunmaktadır. Erektör spina plan bloğu (ESPB), güncel bir rejyonel analjezi tekniği olup alternatif olarak uygulanabilecek basit, güvenli ve etkili bir yöntemdir. Çalışmanın amacı torakotomi sonrası ESPB ve TEA tekniklerinin analjezik etkinliğini değerlendirmektir.



Address for Correspondence: Fatih Şimşek, University of Health Sciences Türkiye, Gülhane Training and Research Hospital, Clinic of Anesthesiology and Reanimation, Ankara, Türkiye

Phone: +90 312 304 59 14 E-mail: drfatihsimsek@gmail.com **ORCID ID:** orcid.org/0000-0002-8774-2861

Received: 15.10.2022 **Accepted:** 28.11.2022

Gereç ve Yöntemler: Bu retrospektif, tek merkezli çalışma Ekim 2018 ile Eylül 2020 arasında yapılmıştır. ESPB, TEA ve konvansiyonel (non-regional) teknik uygulanan 83 hastayı değerlendirdik. Demografik veriler, operasyon tipi ve süresi, postoperatif VAS skorları, opioid tüketimi anestezi ve klinik hasta takip formlarından elde edildi.

Bulgular: Çalışmaya torakotomi uygulanan 83 hasta dahil edildi ve hastalar grup ESPB (28), grup TEA (33) ve herhangi bir rejyonel analjezi yöntemi uygulanmayan grup kontrol (22) olmak üzere üç gruba ayrıldı. Postoperatif 8., 24. ve 48. saatlerde görsel analog ölçek (VAS) skorları, kontrol grubuna göre ESPB ve TEA gruplarında anlamlı olarak düşük bulundu ($p<0,05$). ESPB ve TEA grupları benzer düzeyde VAS skorlarına ve opioid tüketimine sahipti ($p>0,05$). ESPB ve TEA gruplarının opioid tüketimleri kontrol grubuna göre anlamlı derecede düşüktü ($p<0,05$).

Sonuç: Torakotomi sonrası postoperatif analjezi yönetiminde TEA ile benzer düzeyde analjezi sağlayan ESPB, özellikle obezite ve spinal deformite gibi ek hastalıkları bulunan hastalarda iyi bir alternatif rejyonel analjezi tekniği olarak düşünülebilir.

Anahtar Kelimeler: Torasik cerrahi, postoperatif ağrı yönetimi, rejyonel analjezi, epidural analjezi, erektör spina plan bloğu, opioid tüketimi

Introduction

Post-thoracotomy pain is one of the most severe types of postoperative pain. Thoracotomies can cause severe pain and suffering due to multiple muscle incisions, chest drains and possible rib injury (1). Inadequate pain control may cause delay in mobilization, atelectasis, pneumonia, and susceptibility to pulmonary embolism. There are many sensory afferents that transmit pain originating from these damages, and since there is no single analgesic technique that can block these afferents, the analgesic approach should be multimodal. Multimodal analgesia includes systemic analgesia (opioids, non-steroidal anti-inflammatory drugs, paracetamol etc.) and regional anesthesia techniques (2). Good analgesia management allows early mobilization and pulmonary rehabilitation while minimizing the unwanted postoperative effects of pain (3). Opioids are the most commonly used perioperative analgesics, especially for major surgeries such as thoracotomy. However, high doses of opioids cause serious complications such as respiratory depression, nausea, vomiting, itching and constipation (4).

There are different regional anesthesia techniques for postoperative pain management such as thoracic epidural analgesia (TEA), intercostal nerve block, thoracic paravertebral block (TPVB), erector spinae plan block (ESPB). TEA is accepted as the gold standard treatment method in post-thoracotomy pain control (5). This technique, which has been used for many years in post-thoracotomy pain control, also has serious complications such as local anaesthetic toxicity, epidural hematoma, nerve injury, and infection (6). Furthermore TEA, requires a specialist-level practitioner and is not a suitable technique for all patients due to contraindications such as local infection, bleeding disorders (7).

Therefore, while anesthesiologists have turned to new techniques that can be an alternative to TEA in recent years, one of them is ESPB, whose popularity is increasing each day.

ESPB, first described by Forero et al. (8), is a new interfascial block and is widely used in thoracic and abdominal surgeries for postoperative analgesia. ESPB is not only a single-dose block technique, but also be used for catheter applications. The use of this ultrasound-guided peri-paravertebral block technique in thoracotomies is increasing day by day due to its employed a simple and low risk of complications (9).

The aim of this study was to compare the effects of ultrasound-guided ESPB, TEA and conventional (non-regional) technique on postoperative pain scores and opioid (tramadol) consumptions, in thoracotomy.

Material and Methods

This is a retrospective study conducted in a tertiary education and research hospital. After the approval of the Ethics Committee of the University of Health Sciences Türkiye, Gülhane Training and Research Hospital, it was carried out in accordance with the ethical principles stipulated in the Helsinki Declaration (number: 2020-351, date: 24.09.2020).

The perioperative records of patients, the American Society of Anesthesiologists (ASA) 1-3, aged 18-90 years, who underwent elective posterolateral thoracotomy incision (wedge resection, segmentectomy, lobectomy) under general anesthesia by the thoracic surgery clinic, were reviewed retrospectively, between October 2018 and September 2020. The patients were divided into three groups: Those who underwent intraoperative ESP block were group ESPB, those who underwent TEA was group TEA, and those who did not apply any regional analgesia method were control group.

Demographic data: Age (year), gender (female/male), height (cm), weight (kg), ASA (1/2/3), comorbidity (yes/no), recurrent surgery (yes/no) were obtained from the hospital electronic management information system. The type and duration of the operation, postoperative visual analog

scale (VAS) scores, opioid consumption were obtained from anesthesia and clinical patient follow-up forms.

In our center, posterolateral thoracotomy incisions (wedge resection, segmentectomy, lobectomy) are performed under general anesthesia. Standard monitoring (SpO₂, ECG, non-invasive blood pressure) in accordance with ASA criteria is applied for the patients. In addition, invasive arterial monitoring and/or central venous catheterization procedures can be done depending on the size of the surgery or the medical status of the patient. In general anesthesia; 2-3 mg/kg propofol, 1-2 mcg/kg fentanyl and 0.6 mg/kg rocuronium IV are used in induction. Following double-lumen endotracheal tube intubation, anesthesia is performed with inhaled anesthetic and opioid infusion (1-2% sevoflurane + 0.1-0.2 mcg/kg/min. remifentanyl).

All patients are administered 0.6 mg/kg IV meperidine and 10 mg/kg paracetamol IV for postoperative analgesia 20 minutes (min) before the end of the surgery standardly. In our clinic, a regional analgesia method such as ESPB or TEA is applied as a general principle in addition to this standard regimen, depending on the medical status of the patients, experience, and preference of the anesthesiologist. However, a regional analgesia method may not be applied for some patients because of contraindications to regional methods, the patient's disapproval, or technical difficulties.

ESPB is performed at the end of the surgical procedure, under general anesthesia, in the lateral decubitus position, at the level of T5-T6 (surgical incision level) under USG guidance. Spinous processes are displayed by placing the linear ultrasound probe parasagittally in the midline at the T5 level. The probe is then shifted laterally and the transverse processes and erector spinae, rhomboid, and trapezius muscles are displayed. The needle position is confirmed with the help of USG, 0.25% bupivacaine (2.5-3 mg/kg) is injected up to 20 mL into the plane between the erector spinal muscle and the transverse process by advancing the needle in the craniocaudal direction using the "in plane" technique (Figure 1).

Epidural catheter placement for TEA is done at the end of the surgical procedure, under general anesthesia, in the lateral decubitus position. The procedure is often applied at the T5-T6 or T6-T7 level. The loss of resistance technique with saline (SF) is used to determine the epidural space. Controls are performed to exclude intravascular and/or intrathecal catheter placement by placing the catheter in such a way that it remains 4-5 cm in the epidural space. After the patients wake up, they are taken to the postoperative care unit and after standard monitoring, a test dose of 3 mL 1.5% lidocaine with 1:200,000 epinephrine is administered. Then, 5 mL/hour 0.125% bupivacaine infusion is started with the PCA device. Both regional analgesia methods are applied by an anesthesiologist (3 anesthesiologists) with at least 5 years of speciality experience.

The standard analgesia protocol is applied in our hospital for the management of postoperative thoracotomy analgesia, after the patient is sent to the clinic. Diclofenac sodium 75 mg is administered as intramuscular every eight hours. Pain scores are evaluated every 8 hours using the (VAS, 0= no pain, 10= most severe pain). Tramadol IV at a dose of 1 mg/kg is administered as a rescue analgesic to patients with a VAS score >3.

In our center, patients in thoracotomy (wedge resection, segmentectomy, lobectomy) are taken to the operating room without any premedication. All surgical procedures are performed under general anesthesia by applying double lumen tube intubation. All operations are performed by the same surgical team. The operations are performed by making a conventional posterolateral incision of 15-30 cm in the chest, depending on the tumor size and invasion.

Statistical Analysis

The data were evaluated with the "Statistical Package for Social Science (SPSS)" 25.0 software. Categorical data among demographic characteristics were used as numbers (n) and percentage (%), and continuous numerical data were given as mean ± standard deviation. The conformity of continuous data with normal distribution was examined using the Shapiro-Wilk test. One-Way Analysis of Variance was used to compare normally distributed numerical data, and Kruskal-Wallis test was used to compare non-normally distributed numerical data. Mann-Whitney U test was used for intragroup comparisons. Pearson chi-square test was used in the comparison of categorical data. The results were assessed at the 95% confidence interval and the significance level was p<0.05. The significance was assessed at p<0.0167 level by bonferroni correction in group comparisons.

Results

The data of 83 patients were analyzed between October 2018 and September 2020. The data of 28 patients in group ESPB, 33 patients in group TEA, and 22 patients in group control were analyzed retrospectively (Figure 2). No statistically significant difference was observed in the comparison of the groups in terms of demographic data (Table 1) and surgical procedures (Table 2) (p>0.05).

The VAS values of the patients in all three groups at the 8th, 24th and 48th hours in the postoperative period are presented in Table 3. The VAS values in the ESPB and TEA groups at the postoperative 8th, 24th, and 48th hours were found to be statistically significantly lower compared to the control group (p<0.001). No statistically significant difference was determined to be between the VAS values of the ESPB and TEA groups at the postoperative 8th, 24th, and 48th hours in subgroup comparisons (p=0.692/p=0.804/p=0.615).

The tramadol consumption values of the patients in all three groups in the postoperative period are presented in Table 4. Tramadol consumption in ESPB and TEA groups between 0-24, 24-48 and 0-48 hours postoperatively were found to be statistically significantly lower compared to the control group ($p < 0.001$). In subgroup comparisons, no statistically significant difference was observed between the tramadol consumption of ESPB and TEA groups between postoperative 0-24, 24-48 and 0-48 hours ($p = 0.612$ / $p = 0.920$ / $p = 0.600$).

Discussion

In this study, the effects of ESPB and TEA applied after thoracotomy on postoperative VAS scores and tramadol consumption were compared. We have demonstrated that ESPB application provides more effective analgesia compared to the conventional (non-regional) approach in postoperative pain management after thoracotomy. Tramadol consumption decreased significantly in the patients who underwent ESPB. In addition, it was seen that the tramadol consumption values of the ESPB group and the TEA group were at a similar level.

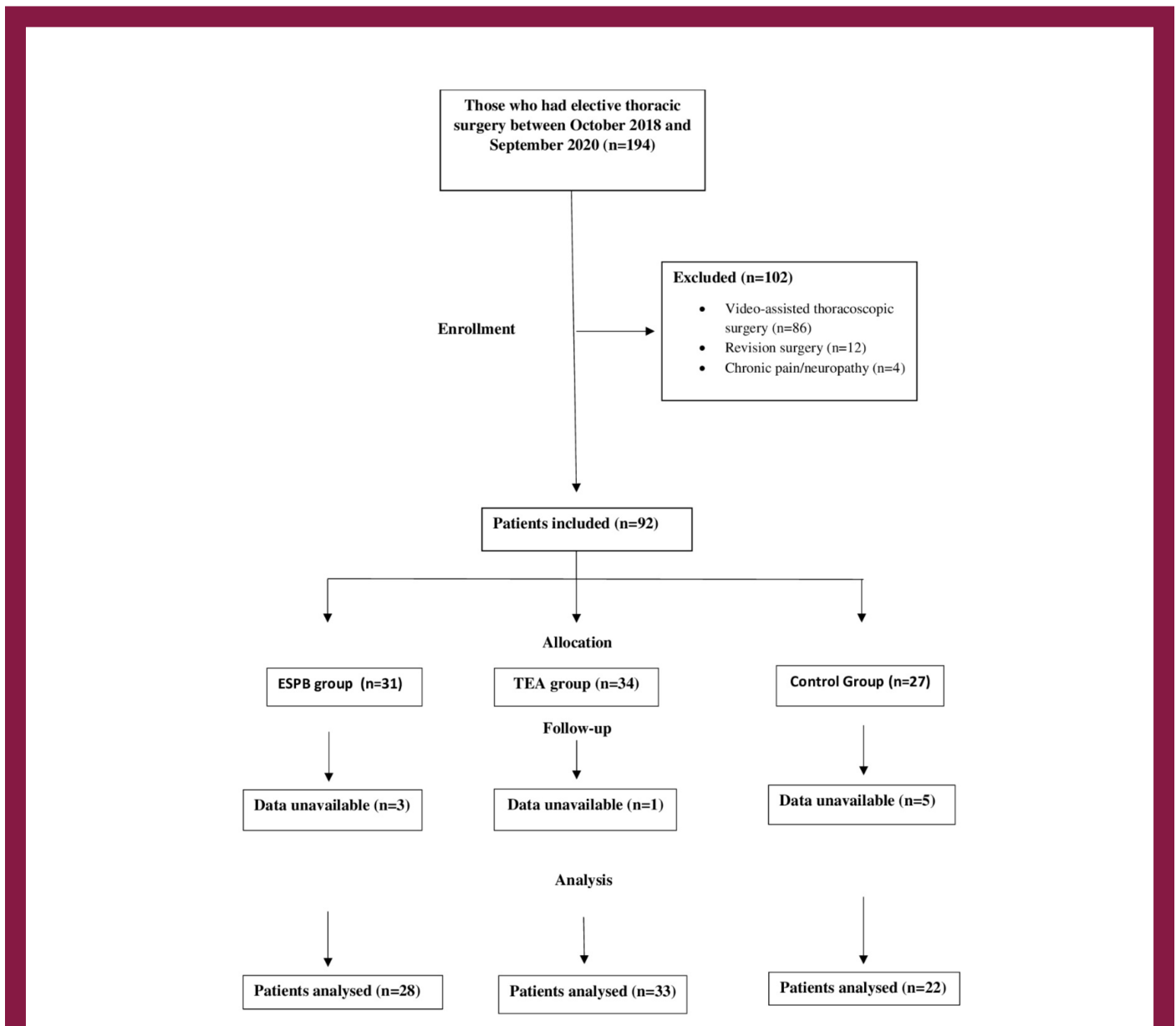
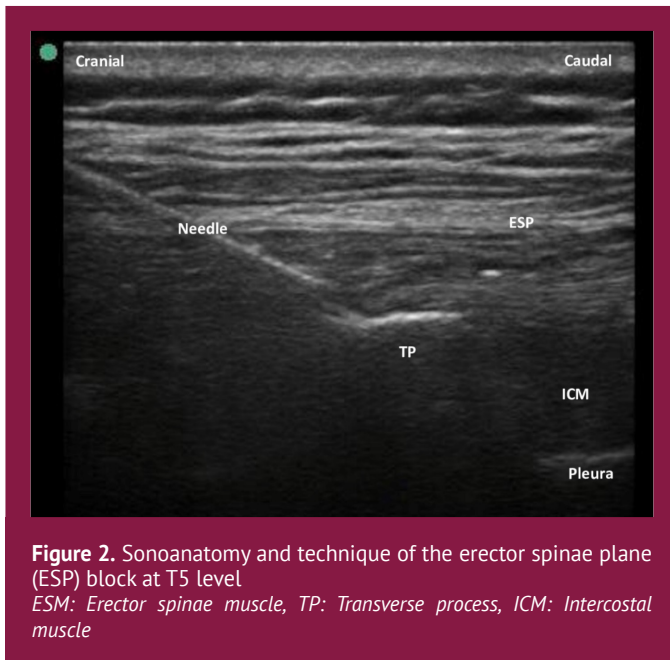


Figure 1. Flow chart of patients selection
 ESPB: Erector spinae plan block, TEA: Thoracic epidural analgesia



In thoracotomy, significant pain and deterioration in lung function occur due to pulmonary parenchymal damage, pleural inflammation, chest wall incision and chest tube placement (10). A good level of postoperative pain management allows for early mobilization and rehabilitation, contributing to the recovery and reducing the time to discharge (11). For this purpose, regional analgesia techniques such as TPVB, TEA, ESPB are applied. TEA, which is considered the gold standard, has serious complications such as nerve damage, pneumothorax, intravenous local anesthetic injection and is contraindicated in the patients with active infection and on anticoagulation therapy (12). On the other hand, ESPB is a new interfascial plane block with a low complication rate that can be applied safely in an effective way (11). It is distinguished from other interfascial plane blocks by being a paraspinal and neuraxial block (13). Application of the block from the operated side and placement of the chest tube make ESPB very safe (14). It is an important advantage that it can be applied easily in the patients with additional difficulties such as morbid obesity

Table 1. Demographic data

	ESPB group (n=28)	TEA group (n=33)	Control group (n=22)	p
Age (years), mean ± SD	56.56±15.83	47.75±19.82	52.96±17	0.196*
Gender, n (%)				
Male	23 (82.1)	27 (81.8)	19 (86.4)	0.894
Female	5 (17.9)	6 (18.2)	3 (13.6)	
Body weight (kg) mean ± SD	75.8±12.9	79.9±16.4	77.6±14.3	0.291**
ASA physical status, n (%)				
ASA II	18 (64.3)	21 (63.6)	14 (63.6)	0.998
ASA III	10 (35.7)	12 (36.4)	8 (36.4)	
Duration of surgery (min.) mean ± SD	165.75±61.42	189.68±82.29	165.70±64.99	0.236**

ESPB: Erector spinae plan block, TEA: Thoracic epidural analgesia, ASA: American society of anesthesiologists, SD: Standard deviation, Min: Minute, *Kruskal-Wallis test was used, **it was compared with ANOVA

Table 2. Comparison of operative procedures (types of surgery), n (%)

	ESPB group (n=28)	TEA group (n=33)	Control group (n=22)	p
Wedge resection	5 (17.9)	11 (33.3)	6 (27.3)	0.704
Segmentectomy	2 (7.1)	4 (12.1)	2 (9.1)	
Lobectomy	19 (67.9)	18 (54.5)	14 (63.6)	

ESPB: Erector spinae plan block, TEA: Thoracic epidural analgesia, Pearson chi-square test was used

Table 3. Postoperative VAS scores (mean ± SD)

	ESPB group (n=28)	TEA group (n=33)	Control group (n=22)	p
8. hour VAS	3.64±1.19 ^a	3.51±1.14 ^a	5.27±1.31 ^b	<0.001
24. hour VAS	2.78±0.99 ^a	2.69±0.84 ^a	4.04 1.04 ^b	<0.001
48. hour VAS	2.10±0.87 ^a	2±0.86 ^a	3.45±0.85 ^b	<0.001

VAS: Visual analog scale, ESPB: Erector spinae plan block, TEA: Thoracic epidural analgesia, SD: Standard deviation, Kruskal-Wallis test was used

Table 4. Postoperative opioid consumption (mean ± SD)

	ESPB group (n=28)	TEA group (n=33)	Control group (n=22)	p
Tramadol 0-24 hour (mg)	112.25±29.13 ^a	109.09±27.53 ^a	217.86±14.06 ^b	<0.001
Tramadol 24-48 hour (mg)	49.90±12.72	50.04±11.32	118.50±15.22	<0.001
Tramadol 0-48 hour (mg)	176.70±28.20 ^a	173.39±26.88 ^a	336.36±26.23 ^b	<0.001

ESPB: Erector spinae plan block, TEA: Thoracic epidural analgesia, SD: Standard deviation, Kruskal-Wallis test was used

or spinal deformities. The popularity of the use of ESPB for postoperative analgesia is increasing as new indications are defined (15). ESPB is effective on both somatic and visceral pain. Thus, it also has a positive effect on the respiratory functions of the patients (16). Wilson et al. (17) have also demonstrated that ESPB applied in a patient with respiratory dysfunction not only provides good analgesia, but also improves the respiratory functions of the patient. Adhikary et al. (18) found that the pain scores of patients who underwent VATS were lower in the ESPB group than in the TEA group. In our study, ESPB and TEA had significantly lower VAS scores than the control group. In addition, VAS scores of ESPB and TEA groups were at similar levels. We think that ESPB, which provides pain control at similar levels to TEA, is a good alternative to TEA due to its ease of application and less complications. But ESPB block has the disadvantage of using ultrasound compared to TEA.

Reducing opioid requirements in the perioperative period is among the goals of good pain management planning. Here, the aim is to provide a good analgesia while reducing all possible side effects due to opioids. Regional anesthesia techniques have an important role in reducing the need for opioids. Bukağıkıran et al. (19) found that opioid consumption at the postoperative 24th hour in patients undergoing thoracic surgery was significantly lower in the ESPB administered group than in the control group. There are studies in the literature demonstrating that both ESPB and TEA reduce opioid consumption in the postoperative period after thoracic surgery (20,21). However, the number of studies comparing these two blocks is limited. Our study findings demonstrate that the total opioid consumption in the ESPB and TEA groups at

the 24th and 48th hours was significantly less compared to the control group. In the comparison of the ESPB and TEA groups, it was found that the opioid consumption rates were similar. Our study findings support the observations obtained from previous case reports.

Study Limitations

This study has some limitations. The sample size of this study is small. Therefore, the results may need to be further validated by a larger sample size test. Another limitation of our study is its retrospective nature. The study could be re-studied prospectively with larger sample sizes test.

Conclusion

ESPB application for postoperative analgesia in thoracotomy can provide a similar level of analgesia to TEA. The technical advantages of ESPB are that it can be applied in a controlled manner, away from the pleura, nerves, and major vascular structures, accompanied by USG. Therefore, ESPB can be considered an effective alternative for postoperative analgesia management after thoracic surgery, especially in patients with additional difficulties such as obesity and spinal deformity where TEA is not possible.

Ethics

Ethics Committee Approval: This single center study was ethically approved by the University of Health Sciences Türkiye, Gülhane Clinical Researchs Ethics Committee (project no: 2020/351, date: 24.09.2020).

Informed Consent: The study was designed retrospectively; no written informed consent form was obtained from patients.

Peer-review: Externally peer-reviewed.

Authorship Contributions

Surgical and Medical Practices: F.Ş., U.T., H.I., Ö.İ., Concept: F.Ş., H.I., Ö.İ., S.Ş., Design: F.Ş., U.T., H.K., G.Ö., Data Collection or Processing: F.Ş., U.T., H.K., Analysis or Interpretation: F.Ş., H.K., H.I., G.Ö., Literature Search: F.Ş., U.T., Ö.İ., Writing: F.Ş., H.K., S.Ş.

Conflict of Interest: No conflict of interest was declared by the authors.

Financial Disclosure: The authors declared that this study received no financial support.

References

1. Duran M, Alparslan V, Yörükoğlu HU, Aksu C, Kuş A. [Erector spinae plane block for a pediatric patient undergoing thoracotomy]. *Agri*. 2022;34:148-150. [\[Crossref\]](#)
2. Forero M, Rajarathinam M, Adhikary S, Chin KJ. Erector spinae plane (ESP) block in the management of post thoracotomy pain syndrome: A case series. *Scand J Pain*. 2017;17:325-359. [\[Crossref\]](#)
3. Sparks A, Stewart JR. Review of Pain Management in Thoracic Surgery Patients, 2018. *J Anesth Clin Res*. 2018;9:4. [\[Crossref\]](#)
4. Wang Q, Zhang G, Wei S, He Z, Sun L, Zheng H. Comparison of the effects of ultrasound-guided erector spinae plane block and wound infiltration on perioperative opioid consumption and postoperative pain in thoracotomy. *J Coll Physicians Surg*. 2019;29:1138-1143. [\[Crossref\]](#)
5. Singh S, Choudhary NK, Lalin D, Verma VK. Bilateral ultrasound-guided erector spinae plane block for postoperative analgesia in lumbar spine surgery: A randomized control trial. *J Neurosurg Anesthesiol*. 2020;32:330-334. [\[Crossref\]](#)
6. Bos EME, Hollmann MW, Lirk P. Safety and efficacy of epidural analgesia. *Curr Opin Anaesthesiol*. 2017;30:736-742. [\[Crossref\]](#)
7. Yeung JH, Gates S, Naidu BV, Wilson MJ, Gao Smith F. Paravertebral block versus thoracic epidural for patients undergoing thoracotomy. *Cochrane Database Syst Rev*. 2016;2:CD009121. [\[Crossref\]](#)
8. Forero M, Adhikary SD, Lopez H, Tsui C, Chin KJ. The erector spinae plane block a novel analgesic technique in thoracic neuropathic pain. *Reg Anesth Pain Med*. 2016;41:621-627. [\[Crossref\]](#)
9. Fang B, Wang Z, Huang X. Ultrasound-guided preoperative single-dose erector spinae plane block provides comparable analgesia to thoracic paravertebral block following thoracotomy: a single center randomized controlled double-blind study. *Ann Transl Med*. 2019;7:174-174. [\[Crossref\]](#)
10. Brocki BC, Westerdahl E, Langer D, Souza DSR, Andreassen JJ. Decrease in pulmonary function and oxygenation after lung resection. *ERJ Open Res*. 2018;4:00055-2017. [\[Crossref\]](#)
11. Chaudhary O, Baribeau Y, Urits I, Sharkey A, Rashid R, Hess P, et al. Use of Erector Spinae Plane Block in Thoracic Surgery Leads to Rapid Recovery From Anesthesia. *Ann Thorac Surg*. 2020;110:1153-1159. [\[Crossref\]](#)
12. Kot P, Rodriguez P, Granell M, Cano B, Rovira L, Morales J, et al. The erector spinae plane block: a narrative review. *Korean J Anesthesiol*. 2019;72:209-220. [\[Crossref\]](#)
13. Chin KJ, Adhikary S Das, Forero M. Erector Spinae Plane (ESP) Block: a New Paradigm in Regional Anesthesia and Analgesia. *Curr Anesthesiol Rep*. 2019;9:271-280. [\[Crossref\]](#)
14. Muñoz F, Cubillos J, Bonilla AJ, Chin KJ. Erector spinae plane block for postoperative analgesia in pediatric oncological thoracic surgery. *Can J Anesth*. 2017;64:880-882. [\[Crossref\]](#)
15. Tulgar S, Selvi O, Senturk O, Serifsoy TE, Thomas DT. Ultrasound-guided Erector Spinae Plane Block: Indications, Complications, and Effects on Acute and Chronic Pain Based on a Single-center Experience. *Cureus*. 2019;11:e3815. [\[Crossref\]](#)
16. Forero M, Rajarathinam M, Adhikary S, Chin KJ. Continuous Erector Spinae Plane Block for Rescue Analgesia in Thoracotomy After Epidural Failure: A Case Report. *A A Case Rep*. 2017;8:254-256. [\[Crossref\]](#)
17. Wilson JM, Lohser J, Klaibert B. Erector Spinae Plane Block for Postoperative Rescue Analgesia in Thoracoscopic Surgery. *J Cardiothorac Vasc Anesth*. 2018;32:e5-e7. [\[Crossref\]](#)
18. Adhikary SD, Pruet A, Forero M, Thiruvankatarajan M. Erector spinae plane block as an alternative to epidural analgesia for post-operative analgesia following video-assisted thoracoscopic surgery: A case study and a literature review on the spread of local anaesthetic in the erector spinae plane. *Indian J Anaesth*. 2018;62:75-78. [\[Crossref\]](#)
19. Bukağıkıran O, Kuzucuoğlu T, Yuce Y, Geyik FD, Cevik B. The effects of ultrasound guided erector spinae plane block on postoperative analgesia in elective thoracic surgery. *South Clin Ist Euras*. 2021;32:316-322. [\[Crossref\]](#)
20. Gürkan Y, Aksu C, Kuş A, Yörükoğlu UH, Kılıç CT. Ultrasound guided erector spinae plane block reduces postoperative opioid consumption following breast surgery: A randomized controlled study. *J Clin Anesth*. 2018;50:65-68. [\[Crossref\]](#)
21. Güven BB, Ertürk T, Ersoy A. Postoperative analgesic effectiveness of bilateral erector spinae plane block for adult cardiac surgery: a randomized controlled trial. *J Health Sci Med*. 2022;5:150-155. [\[Crossref\]](#)